

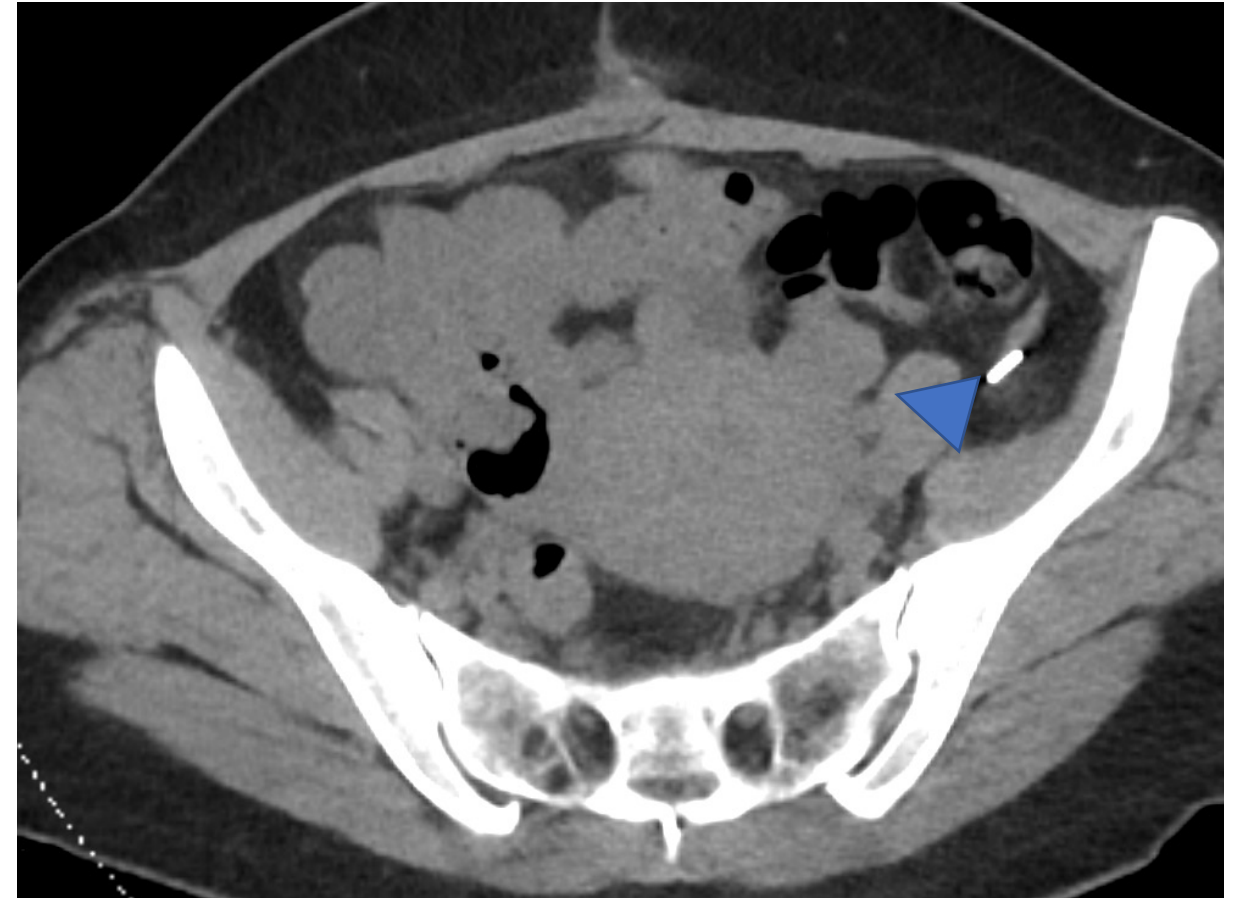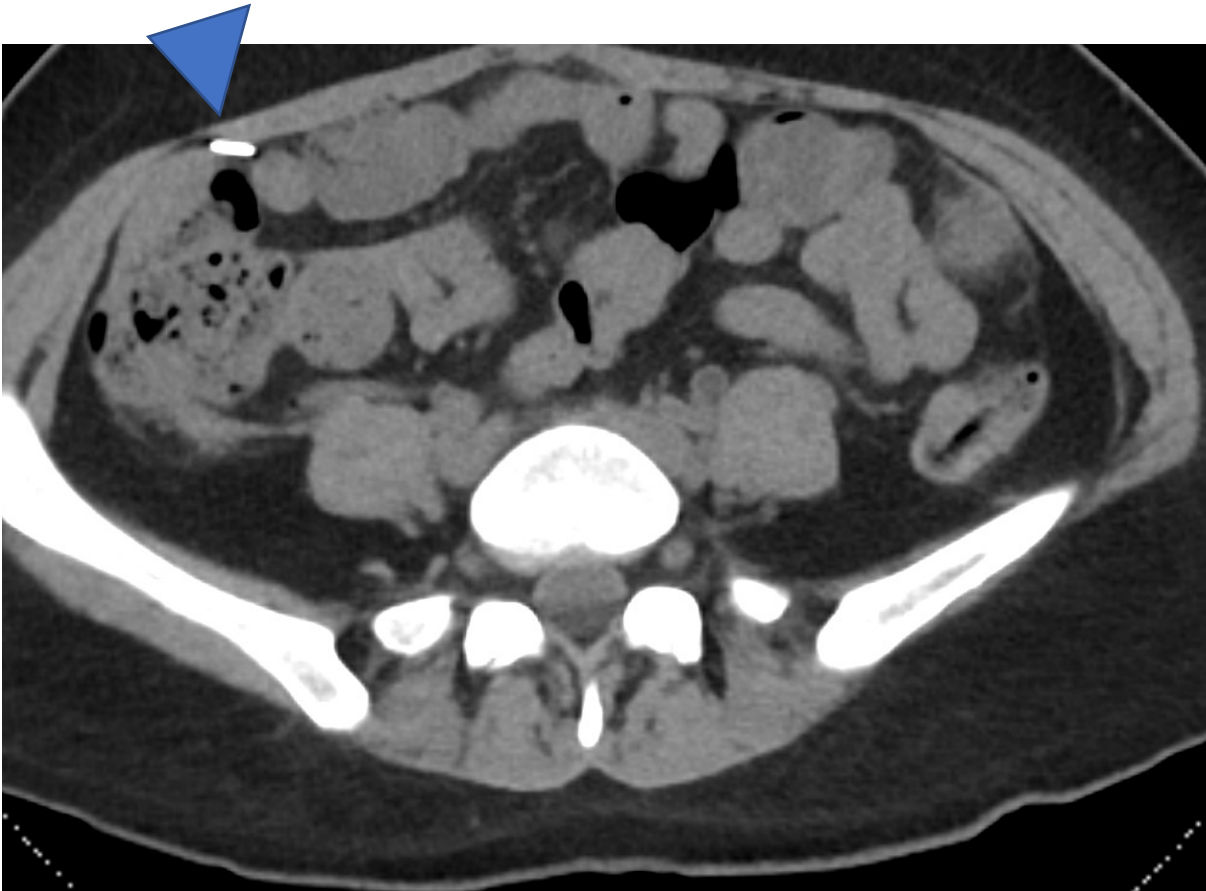
# Ovarian Transposition

Helen Xu, MD  
Stanford University  
Body Imaging Fellow

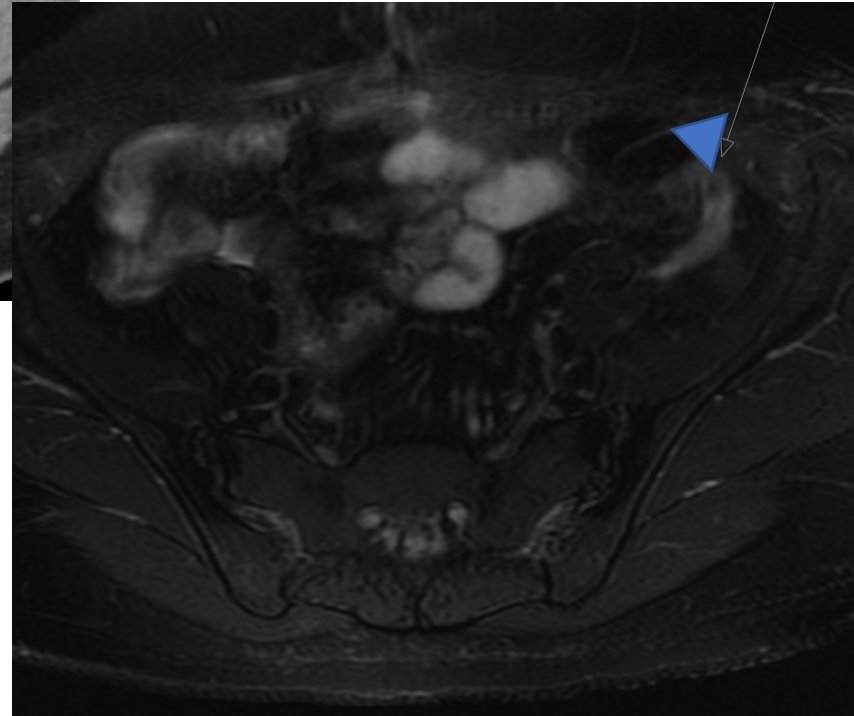
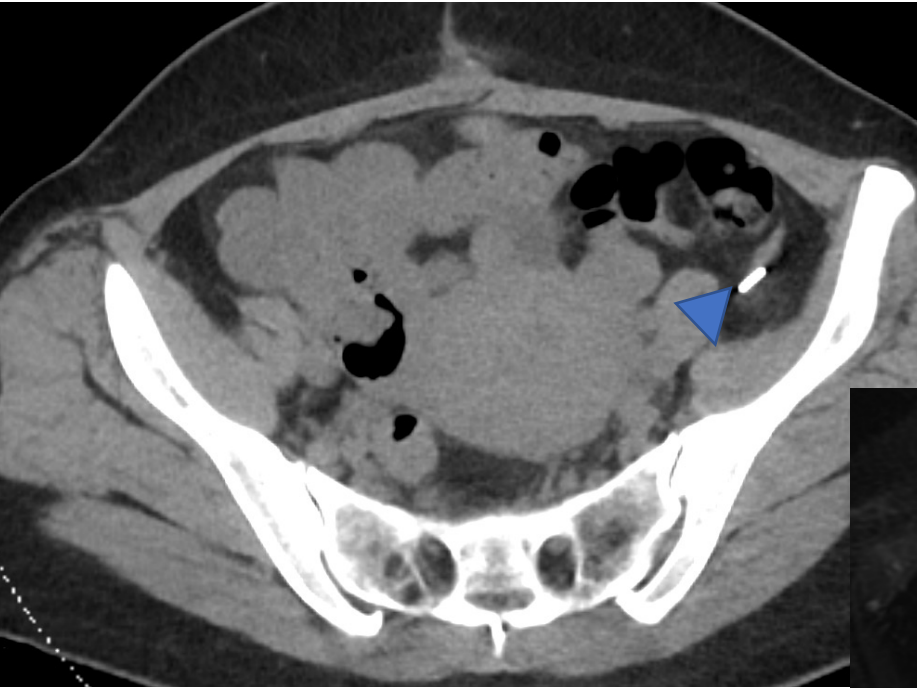*Special thanks to Dr. Lu Shen for her  
contributions!*



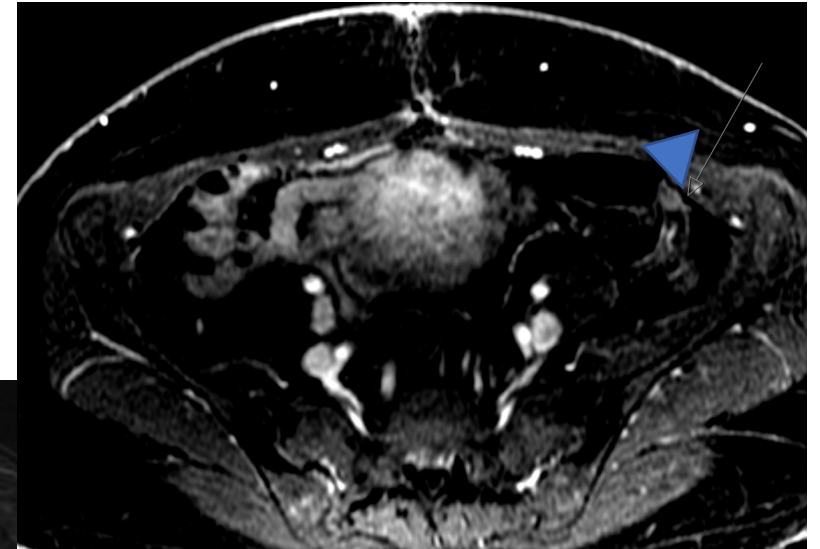
# CT – Bilateral Surgical Clips denoting oophorectomy



# CT with MR correlates for left ovary



• Ax T2 FS



• Ax Post Contrast